

# Retrospective evaluation of the efficacy of ultrasound-guided intra-articular hyaluronic-acid-based injections (Hyalubrix®) in patients with glenohumeral osteoarthritis

Lorenzo Monti,<sup>1</sup> Emanuele Franchi,<sup>2</sup> Francesco Verde,<sup>1</sup> Stefano Sgherzi,<sup>3</sup> Filippo Maria Anghilieri<sup>2</sup>

<sup>1</sup>Minimally Invasive and Robotic Prosthetic Surgery of Hip and Knee Unit, Department of Orthopedics, IRCCS San Raffaele Hospital, Milan; <sup>2</sup>Department of Orthopedics, Villa Aprica Clinical Institute, Como; <sup>3</sup>ASST Rhodense, Milan, Italy

**Correspondence:** Lorenzo Monti, Minimally Invasive and Robotic Prosthetic Surgery of Hip and Knee Unit, Department of Orthopedics, IRCCS San Raffaele Hospital, via Olgettina 60, Milan, Italy. Tel.: +39 338 157 2134.  
E-mail: monti.lorenzo@hsr.it

**Key words:** hyalubrix, intra-articular injections, glenohumeral osteoarthritis, hyaluronic acid.

## Summary

**Objective.** Intra-articular injections of hyaluronic acid (HA) have been reported to alleviate pain, reduce disability, and improve joint function in glenohumeral osteoarthritis (GH-OA). This retrospective study aimed to evaluate the effectiveness of a HA-based formulation (Hyalubrix®) in reducing the pain of patients with GH-OA and improving both patient's shoulder functions and quality of life (QoL).

**Methods.** Data collected during the standard clinical practice of the center was retrospectively analyzed. The Simple Shoulder Test (SST) questionnaire reported data on the patient's ability to perform daily activities; the Euro-Quality of Life Health Assessment (EQ-5D) collected evidence on QoL; and changes in pain were evaluated through the Visual Analog Scale (VAS). SST and EQ-5D scores were analyzed comparing baseline values with those at the last follow-up, while VAS was investigated for all the available visits. Continuous values were summarized as mean  $\pm$  standard deviation, median, and 25-75<sup>th</sup> percentiles. The Shapiro-Wilk test assessed normality, with significance set at  $p < 0.05$ , and no adjustments for multiple comparisons were made.

**Results.** All scores showed a significant improvement: VAS decreased from  $55.4 \pm 13.8$  to  $16.2 \pm 16.3$  ( $p < 0.001$ ), the SST increased from 38.0 to 65.5 ( $p < 0.001$ ), as did the EQ-5D (from 41.7 to 76.7;  $p < 0.001$ ).

**Conclusions.** GH-OA treatment with Hyalubrix® proved to be highly beneficial, leading to complete pain reduction in more than 50% of patients and a significant reduction in 27.5% of cases. This resulted in improved joint function and QoL.

## Introduction

Osteoarthritis (OA) is the leading cause of disability in the elderly and a significant socioeconomic burden for patients and the health care system (1, 2). Glenohumeral osteoarthritis (GH-OA), also known as shoulder OA, is a degenerative joint disease (3, 4). The prevalence of shoulder OA has not been extensively studied but has generally been estimated broadly at 4-26% (5), and population-based studies have demonstrated that 16.1-20.1% of adults over 65 years of age have radiographic evidence of GH-OA (6, 7).

The exact cause of GH-OA is often unknown, but several factors are known to contribute to its development: age; the repetitive use of the shoulder joint in certain occupations or athletic activities; a previous shoulder injury; and genetic predisposition (8).

Shoulder arthroplasty is a definitive surgical treatment for GH-OA, which effectively relieves pain and improves range of motion but is associated with significant cost and morbidity (9, 10). In clinical practice, several nonsurgical, conservative treatment options are available for GH-OA, including physical therapy, analgesics, nonsteroidal and steroidal anti-inflammatory drugs, and corticosteroid injections. Among conservative treatments, viscosupplementation with hyaluronic acid (HA), a naturally occurring substance found in the synovial fluid of healthy joints, is widely used in clinical practice (11-13). HA is a non-sulfated glycosaminoglycan involved in the maintenance of chondrocyte function and synovial fluid viscoelasticity (13,14). In the context of GH-OA, the lower concentration and molecular weight of HA decrease synovial fluid viscoelasticity and increase friction between joint surfaces, leading to cartilage wear (15). The goal of viscosupplementation is to alleviate symptoms by supplementing the natural HA in the joint and improve the viscoelasticity of synovial fluid, ultimately reducing disability and improving joint function. Numerous studies have reported that intra-articular injection of HA is well tolerated and results in statistically significant pain reduction (16-22). Several products based on HA are now available on the market, and there is extensive clinical evidence for their efficacy and safety in the treatment of knee and hip OA (23-25). However, few studies have investigated the efficacy of HA in the treatment of GH-OA.

Hyalubrix® (Fidia Farmaceutici S.p.A, Abano Terme, Italy) is a sterile non-pyrogenic solution of HA sodium salt with a molecular weight  $>1500$  kDa produced by bacterial fermentation. Hyalubrix® has been successfully used in the treatment of knee and hip OA (26-28) and a prospective observational study evaluating its clinical efficacy and safety in all types of OA synovial joints concluded that the treatment relieved pain, improved mobility, and increased the quality of life of participants (29).

This study aimed to evaluate the efficacy of intra-articular Hyalubrix® injections on pain, on the ability of patients with GH-OA to perform daily activities, and on the improvement of their quality of life.

## Materials and Methods

This retrospective, observational cohort study examines patients with GH-OA who received three intra-articular injections of HA administered at weekly intervals. Patients were eligible for inclusion in the retrospective analysis if they met the following criteria: men or women aged 18 to 70 years; the presence of signs and symptoms associated with GH-OA, including radiologically confirmed grade II-IV GH-OA according to Kellgren Lawrence criteria, symptomatic history of chronic pain for at least 6 months but less than 2 years, shoulder pain with movement and at rest; limitation of range of motion; discontinuation of nonsteroidal anti-inflammatory drugs or analgesic medications at least 72 hours prior to the first visit; rotator cuff integrity confirmed by ultrasound or magnetic resonance imaging assessment, allowing for the exclusion of subjects with full-thickness tendon tears. The exclusion criteria were: patients with concomitant joint disease (rotator cuff tears, adhesive capsulitis, previous shoulder surgery, previous humeral head fractures, calcium pyrophosphate deposition disease, cervical spine disease, rheumatoid arthritis, or any other immune conditions leading to shoulder arthritis); patients with grade I OA and those with grade IV OA with indication to shoulder arthroplasty; use of systemic corticosteroids (except inhaled or topical corticosteroids) or intraarticular injections of corticosteroids into the

treated shoulder 3 months prior to the baseline visit; HA injections into the treated shoulder 6 months prior to the baseline visit. Patients with Kellgren-Lawrence grade 2-3 OA with rotator cuff tendinosis were included.

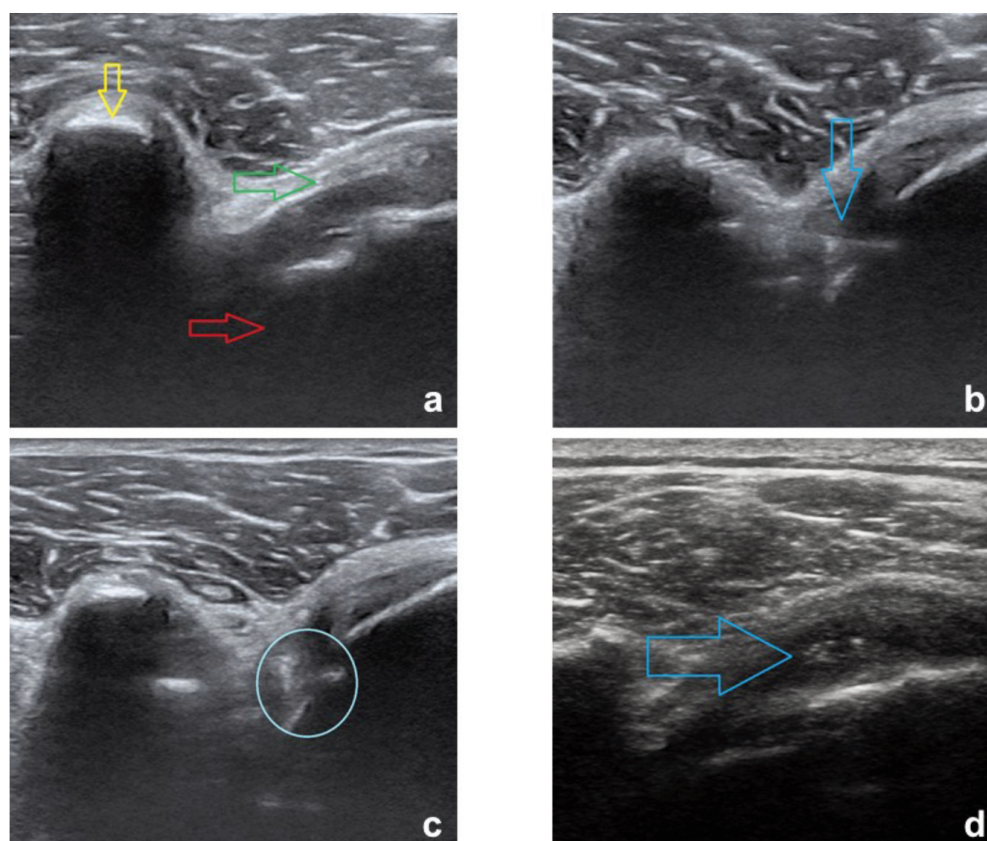
Participants were given a detailed information sheet about the study, which was also shared with their primary care physician.

### Hyaluronic acid injection

Each patient received a total of three IA injections of Hyalubrix® at weekly intervals. The injection was made using a standardized technique for all patients: an ultrasound examination was performed to be sure to inject HA in the joint space. The injections were performed anteriorly, with the patient sitting with the shoulders relaxed, slightly inverted, and the elbows flexed at approximately 90° with forearms resting on the knees. The needle was inserted medial to the head of the humerus, 1cm lateral to the coracoid process, and directed posteriorly at a slightly superior and lateral angle (Figure 1). During the injection, the HA should flow unhindered and without forcing the syringe pump. Patients were instructed to rest for about 24 hours and local ice was suggested three times a day for a couple of days.

### Data collection

Demographic data (age, sex, comorbidities) at baseline (V1)



**Figure 1.** Ultrasound images of intra-articular treatment with hyaluronic acid (HA). **a)** Joint recess between the humeral head (red arrow) and the coracoid (yellow arrow) using an anterior approach, below the subscapularis tendon (green arrow); **b)** needle shaft (blue arrow) directed towards the humeral head; **c)** HA injection once mechanical “stop” on the surface of the head is achieved, with the material visible in the joint (blue circle); **d)** needle withdrawal and subsequent verification of proper technique execution by observing the injected HA (blue arrow) along the bone surface, beneath the expanded capsule and tendon plane.

were analyzed. To evaluate the effectiveness of the treatment, data from different scales and questionnaires, usually used during standard clinical practice at the center, were collected and analyzed: the ability of the affected shoulder to perform activities of daily living was assessed with the Simple Shoulder Test (SST) questionnaire; patients' quality of life was assessed with the Euro-Quality of Life Health Assessment (EQ-5D) (<https://euroqol.org/eq-5d-instruments/>); a Visual Analog Scale (VAS) was used to assess pain. SST and EQ-5D scores were analyzed by comparing baseline values (V1) with those at the last follow-up (V5), while VAS was investigated for all the available visits (V1, V2, V3, V4, and V5).

Inflammatory changes involving muscle and ligament structures, identified through clinical diagnosis or functional assessment focused on pain (positive results on the palm-up and Yergason tests) were recorded and included in the analysis. Additionally, evidence from ultrasonographic evaluation aimed at assessing synovial tissue was included in the analysis when employed to identify residual inflammation and pain. Because the data were scattered around the visit time points due to the retrospective study design, we performed a score difference analysis by comparing the baseline score with each subsequent follow-up visit, regardless of the time interval between visits.

## Statistical analysis

Continuous values were summarized as mean  $\pm$  standard deviation, median, and 25-75th percentiles. The normality assumption for continuous variables was tested using the Shapiro-Wilk test. All statistical tests were two-sided and  $p < 0.05$  were considered statistically significant. No adjustment was made for multiple comparisons. All analyses were performed using SAS 9.4 (SAS Institute, Cary, NC, USA).

## Results

According to the eligibility criteria, 42 records were analyzed: 23 patients (56%) were men and 19 (46%) were women, with a mean age of  $67.2 \pm 9.9$  years and a median age of 65.5 years (range: 50-91 years). The reported comorbidities were hypertension (40%), hypothyroidism (7%), dyslipidemia (12%), cardiopathy (17%), osteoporosis (7%), peripheral vascular disease (2%), diabetes mellitus (5%), and depression (2%). The retrospective design resulted in variable visits, not scheduled on a regular and consistent basis, as outlined in Table 1, which presents mean and median intervals between baseline (V1) and subsequent visits, along with participation rates. Among the 42 patient records, two had missing

follow-ups, and their data were excluded from the analysis. Additionally, some clinical records lacked information on the defined endpoints; therefore, the specific data availability used for the analysis of each endpoint is detailed in the corresponding tables. In patients affected by shoulder OA and treated with HA injections, the behavior of the mean VAS at each visit (Table 2) shows a clear downward trend of pain from baseline ( $55.4 \pm 13.8$ ) to V5 ( $16.2 \pm 16.3$ ). When we examined the mean differences of the VAS value ( $\Delta$  VAS), baseline VAS decreased by 25.8 points on average at V2 and by 39.8 points at V5 (Table 2). Interestingly, the decrease in VAS value at V3 was similar to that at V4 and V5, indicating an early effect of HA, which then leveled off. The differences between the mean VAS and mean  $\Delta$  VAS values were statistically significant ( $p < 0.001$ ) compared to baseline. Overall, of the patients who continued treatment, 20 achieved complete pain reduction (VAS=0), 11 continued to have mild pain (VAS<20), mainly in the anterior region and/or at the level of the long head of the biceps, 8 continued other therapies (physio kinesiotherapy/physiotherapy/shock waves/ozone therapy) aimed at treating muscle and tendon inflammation, despite the strong improvement; finally, 1 patient still had a VAS of 40 and was referred for surgery.

Table 3 shows the mean SST score, a measure of the ability of the affected shoulder to perform activities of daily living, at visit 5 compared with baseline. It showed a significant increase, from a baseline value of 38.0 at V1 to 65.5 at V5 ( $p < 0.001$ ). To determine whether viscosupplementation with high molecular weight HA improves the quality of life of patients with shoulder OA, we analyzed EQ-5D questionnaires. The EQ-5D score increased from a mean baseline score of 41.7 to 76.7 at T5, or 38.1 points (Table 4) ( $p < 0.001$ ). It is important to note that both SST and EQ-5D scores were assessed only at baseline and V5, not at intermediate visits.

**Table 1.** Days elapsed between baseline and subsequent visits.

Visit	Mean $\pm$ SD	Median (25-75 <sup>th</sup> percentile)
V2	17.8 $\pm$ 51.8	7.0 (7.0-8.0)
V3	37.0 $\pm$ 76.9	14.0 (14.0-17.0)
V4	127.8 $\pm$ 85.8	114.0 (91.0-140.0)
V5	218.4 $\pm$ 92.8	209.0 (154.0-245.0)

SD, standard deviation.

**Table 2.** Visual Analog Scale score summary statistics at each visit.

Visit	N	VAS	$\Delta$ VAS from T1	p
V1	38	55.4 $\pm$ 13.8 50.0 (50.0-60.0)	-	-
V2	38	31.6 $\pm$ 17.3 30.0 (20.0-40.0)	-25.8 $\pm$ 13.8 -30.0 (-32.0,20.0)	<0.001
V3	39	16.8 $\pm$ 12.6 15.0 (10.0-24.0)	-40.0 $\pm$ 12.7 -40.0 (-50.0,35.0)	<0.001
V4	39	16.1 $\pm$ 14.3 10.0 (0.0-25.0)	-39.5 $\pm$ 16.6 -40.0 (-50.0,30.0)	<0.001
V5	38	16.2 $\pm$ 16.3 10.0 (5.0-20.0)	-39.8 $\pm$ 17.67 -40.0 (-50.0,30.0)	<0.001

Mean  $\pm$  standard deviation; median (25<sup>th</sup>, 75<sup>th</sup> percentile). VAS, Visual Analog Scale.



## Discussion

Shoulder OA is a degenerative joint disease characterized by the deterioration of cartilage in the shoulder joint, leading to symptoms such as pain, stiffness, limited range of motion and difficulty in performing movements of the shoulder, weakness, and inflammation. Intra-articular injections of high molecular weight HA have been used as a treatment option for OA, including shoulder OA, due to HA's lubricating and shock-absorbing properties within the joint. We investigated the efficacy of intra-articular HA injections using Hyalubrix® in patients with GH-OA, evaluating pain reduction, improved daily function, and enhanced quality of life through questionnaires assessing VAS, SST, and EQ-5D scores, respectively. Our results strongly suggest that this treatment was highly beneficial, resulting in the disappearance of pain in more than 50% of patients, with an additional 27.5% of patients reporting dramatic pain reduction, largely improved joint function, and improved quality of life. Our findings are consistent with previous work on the use of HA for the treatment of shoulder OA. A systematic review published in 2014 analyzed the results of several randomized controlled trials that examined the use of HA injections for shoulder OA (30). It showed that injections of HA resulted in significant reductions in pain and improvements in shoulder function compared with placebo injections (30). These conclusions were confirmed by a subsequent review and meta-analysis, which showed that intra-articular injections of HA are safe and improve pain in patients with GH-OA (31). A prospective evaluation of intra-articular injection of HA for the treatment of shoulder OA also found that this treatment was well tolerated and that there were clinically and statistically significant improvements in shoulder pain throughout the 6-month study period, which were associated with improved overall patient assessment scores (32).

In addition, patients treated with intra-articular injection in combination with a physical exercise program had significantly greater decreases in shoulder pain at the 3- and 6-month follow-up than patients in the control group who participated in a physical exercise program only. Moreover, this study found a significant long-term improvement in the range of motion and ability to perform daily activities between the two groups (18). This study also confirmed that treatment with intra-articular injections of HA can be combined with other therapies to increase its efficacy in more

complex clinical conditions. In our study, we found that 11 patients required physical therapy or other additional treatments to further reduce VAS. This is because injections of HA act on the joint but do not improve other inflammatory conditions involving muscle and ligament structures, in particular, the long head of the bicep's tendon. However, HA, in combination with other treatments, such as physical therapy, can lead to complete remission of symptoms.

Because this was a retrospective study, our conclusions are limited. While retrospective studies offer the opportunity to analyze data from a real-world healthcare setting, they also have inherent variability. Factors such as outpatient clinic availability, patient adherence to scheduled visits, and incomplete medical records can influence the reliability and consistency of the data collected, potentially impacting the interpretation of our findings. In addition, data from a relatively small number of patients were included, making it difficult to determine the extent to which concomitant factors may have influenced the study results.

Although the efficacy of HA in the treatment of GH-OA remains to be confirmed by larger, controlled studies, our work provides further evidence that intra-articular HA injections, both alone and in combination with adjunctive treatments such as physical therapy, can relieve pain, improve joint function, increase the ability to perform activities of daily living and lead to improved overall quality of life in patients with shoulder OA.

## Conclusions

In summary, the findings from this retrospective study confirm the efficacy of Hyalubrix® in the treatment of GH-OA. The intra-articular injections of this HA-based formulation demonstrated a remarkable impact on pain reduction, significantly enhancing the quality of life and shoulder functions of patients. The robust improvements observed in all assessed parameters, as evidenced by the substantial decrease in VAS scores, enhancement in SST scores, and notable improvement in EQ-5D scores, contribute valuable insights into the clinical effectiveness of Hyalubrix® as a therapeutic intervention for GH-OA. Further prospective comparative studies are warranted to validate and build upon these promising findings, paving the way for optimized and evidence-based management of GH-OA.

**Table 3.** Simple Shoulder Test score summary statistics.

Visit	N	SST	N	Δ SST from T1	p
V1	36	38.0±18.4 33.3 (25.0-50.0)		-	-
V5	35	65.5±19.1 75.0 (41.7-83.3)	36	27.2±19.0 20.9 (16.6-41.6)	<0.001

Mean ± standard deviation; median (25<sup>th</sup>, 75<sup>th</sup> percentile). SST, Simple Shoulder Test.

**Table 4.** Euro-Quality of Life Health Assessment summary statistics.

Visit	N	EQ-5D	Δ EQ-5D I	p
V1	36	41.7±32.2 59.0 (12.0-66.0)	-	-
V5	36	76.7±18.9 76.0 (66.0-93.0)	38.1±26.9 26.0 (20.0-59.0)	<0.001

Mean ± standard deviation; median (25<sup>th</sup>, 75<sup>th</sup> percentile). EQ-5D, Euro-Quality of Life Health Assessment.

## References

1. Issa SN, Sharma L. Epidemiology of osteoarthritis: an update. *Curr Rheumatol Rep* 2006; 8: 7-15.
2. Neogi T, Zhang Y. Epidemiology of osteoarthritis. *Rheum Dis Clin North Am* 2013; 39: 1-19.
3. Chillemi C, Franceschini V. Shoulder osteoarthritis. *Arthritis* 2013; 2013: 370231.
4. Zhang Y, Jordan JM. Epidemiology of osteoarthritis. *Clin Geriatr Med* 2010; 26: 355-69. Erratum in: *Clin Geriatr Med* 2013; 29: ix.
5. Thomas M, Bidwai A, Rangan A, Rees JL, Brownson P, Tennent D, et al. Glenohumeral osteoarthritis. *Shoulder Elbow* 2016; 8: 203-14.
6. Kobayashi T, Takagishi K, Shitara H, Ichinose T, Shimoyama D, Yamamoto A, et al. Prevalence of and risk factors for shoulder osteoarthritis in Japanese middle-aged and elderly populations. *J Shoulder Elbow Surg* 2014; 23: 613-9.
7. Oh JH, Chung SW, Oh CH, Kim SH, Park SJ, Kim KW, et al. The prevalence of shoulder osteoarthritis in the elderly Korean population: association with risk factors and function. *J Shoulder Elbow Surg* 2011; 20: 756-63.
8. Kerr R, Resnick D, Pineda C, Haghighi P. Osteoarthritis of the glenohumeral joint: a radiologic-pathologic study. *AJR Am J Roentgenol* 1985; 144: 967-72.
9. Sperling JW, Hawkins RJ, Walch G, Mahoney AP, Zuckerman JD. Complications in total shoulder arthroplasty. *Instr Course Lect* 2013; 62: 135-41.
10. van de Sande MA, Brand R, Rozing PM. Indications, complications, and results of shoulder arthroplasty. *Scand J Rheumatol* 2006; 35: 426-34.
11. Al-Mohrej OA, Prada C, Leroux T, Shanthanna H, Khan M. Pharmacological treatment in the management of glenohumeral osteoarthritis. *Drugs Aging* 2022; 39: 119-28.
12. Costa FR, Costa Marques MR, Costa VC, Santos GS, Martins RA, Santos MDS, et al. Intra-articular hyaluronic acid in osteoarthritis and tendinopathies: molecular and clinical approaches. *Biomedicines* 2023; 11: 1061.
13. Strauss EJ, Hart JA, Miller MD, Altman RD, Rosen JE. Hyaluronic acid viscosupplementation and osteoarthritis: current uses and future directions. *Am J Sports Med* 2009; 37: 1636-44.
14. Patti AM, Gabriele A, Vulcano A, Ramieri MT, Della Rocca C. Effect of hyaluronic acid on human chondrocyte cell lines from articular cartilage. *Tissue Cell* 2001; 33: 294-300.
15. Dahl LB, Dahl IM, Engström-Laurent A, Granath K. Concentration and molecular weight of sodium hyaluronate in synovial fluid from patients with rheumatoid arthritis and other arthropathies. *Ann Rheum Dis* 1985; 44: 817-22.
16. Blaine T, Moskowitz R, Udell J, Skyhar M, Levin R, Friedlander J, et al. Treatment of persistent shoulder pain with sodium hyaluronate: a randomized, controlled trial. A multicenter study. *J Bone Joint Surg Am* 2008; 90:970-9.
17. Di Giacomo G, de Gasperis N. Hyaluronic acid intra-articular injections in patients affected by moderate to severe glenohumeral osteoarthritis: a prospective randomized study. *Joints* 2017; 5: 138-42.
18. Di Giacomo G, de Gasperis N. Glenohumeral osteoarthritis treatment with a single hyaluronic acid administration: clinical outcomes. *J Biol Regul Homeost Agents* 2021; 35: 657-61.
19. Kwon YW, Eisenberg G, Zuckerman JD. Sodium hyaluronate for the treatment of chronic shoulder pain associated with glenohumeral osteoarthritis: a multicenter, randomized, double-blind, placebo-controlled trial. *J Shoulder Elbow Surg* 2013; 22: 584-94.
20. Merolla G, Bianchi P, Porcellini G. Ultrasound-guided subacromial injections of sodium hyaluronate for the management of rotator cuff tendinopathy: a prospective comparative study with rehabilitation therapy. *Musculoskelet Surg* 2013; 97: 49-56.
21. Porcellini G, Merolla G, Giordan N, Paladini P, Burini A, Cesari E, et al. Intra-articular glenohumeral injections of HYADD®4-G for the treatment of painful shoulder osteoarthritis: a prospective multicenter, open-label trial. *Joints* 2016; 3: 116-21.
22. Weil AJ. High molecular weight hyaluronan for treatment of chronic shoulder pain associated with glenohumeral arthritis. *Med Devices* 2011; 4: 99-105.
23. Migliore A, Tormenta S, Martin Martin LS, Iannesi F, Massafra U, Carloni E, et al. The symptomatic effects of intra-articular administration of hylan G-F 20 on osteoarthritis of the hip: clinical data of 6 months follow-up. *Clin Rheumatol* 2006; 25: 389-93.
24. Phiphobmongkol V, Sudhasaneya V. The effectiveness and safety of intra-articular injection of sodium hyaluronate (500-730 kDa) in the treatment of patients with painful knee osteoarthritis. *J Med Assoc Thai* 2009; 92: 1287-94.
25. Stitik TP, Blacksin MF, Stiskal DM, Kim JH, Foye PM, Schoenherr L, et al. Efficacy and safety of hyaluronan treatment in combination therapy with home exercise for knee osteoarthritis pain. *Arch Phys Med Rehabil* 2007; 88: 135-41.
26. Giarratana LS, Marelli BM, Crapanzano C, De Martinis SE, Gala L, Ferraro M, et al. A randomized double-blind clinical trial on the treatment of knee osteoarthritis: the efficacy of polynucleotides compared to standard hyaluronan viscosupplementation. *Knee* 2014; 21: 661-8.
27. Mauro GL, Sanfilippo A, Scaturro D. The effectiveness of intra-articular injections of Hyalubrix® combined with exercise therapy in the treatment of hip osteoarthritis. *Clin Cases Miner Bone Metab* 2017; 14: 146-52.
28. Migliore A, Massafra U, Frediani B, Bizzi E, Sinelnikov Yzchaki E, et al. HyalOne® in the treatment of symptomatic hip OA - data from the ANTIAGE register: seven years of observation. *Eur Rev Med Pharmacol Sci* 2017; 21: 1635-44.
29. Foti C, Cisari C, Carda S, Giordan N, Rocco A, Frizziero A, et al. A prospective observational study of the clinical efficacy and safety of intra-articular sodium hyaluronate in synovial joints with osteoarthritis. *Eur J Phys Rehabil Med* 2011; 47: 407-15.
30. Colen S, Geervliet P, Haverkamp D, Van Den Bekerom MP. Intra-articular infiltration therapy for patients with glenohumeral osteoarthritis: a systematic review of the literature. *Int J Shoulder Surg* 2014; 8: 114-21.
31. Zhang B, Thayaparan A, Horner N, Bedi A, Alolabi B, Khan M. Outcomes of hyaluronic acid injections for glenohumeral osteoarthritis: a systematic review and meta-analysis. *J Shoulder Elbow Surg* 2019; 28: 596-606.
32. McKee MD, Litchfield R, Hall JA, Wester T, Jones J, Harrison AJ. NASHA hyaluronic acid for the treatment of shoulder osteoarthritis: a prospective, single-arm clinical trial. *Med Devices* 2019; 12: 227-34.

**Contributions:** all the authors made a substantial intellectual contribution, read and approved the final version of the manuscript, and agreed to be accountable for all aspects of the work.

**Conflict of interest:** the authors do not have any potential conflicts of interest for this manuscript.

**Ethics approval and consent to participate:** all data are anonymous and retrospectively analyzed. Patients were treated according to the best clinical practice and no additional or experimental exams or treatments were performed. All procedures performed were in accordance with the 1964 Helsinki Declaration and its later amendments or comparable ethical standards. For this type of study, formal consent was not required in our center.

**Informed consent:** there is no information (names, initials, hospital identification numbers, or photographs) in the submitted manuscript that can be used to identify patients.

**Availability of data and materials:** data and materials are available from the corresponding author upon request.

**Funding:** the authors received no financial support for the preparation, research, authorship, and publication of this manuscript.

Received: 25 January 2024.

Accepted: 14 July 2024.

Early access: 16 December 2024.

This work is licensed under a Creative Commons Attribution-NonCommercial 4.0 International License (CC BY-NC 4.0).

©Copyright: the Author(s), 2024

Licensee PAGEPress, Italy

Reumatismo 2025; 77:1699

doi:10.4081/reumatismo.2024.1699

*Publisher's note: all claims expressed in this article are solely those of the authors and do not necessarily represent those of their affiliated organizations, or those of the publisher, the editors and the reviewers. Any product that may be evaluated in this article or claim that may be made by its manufacturer is not guaranteed or endorsed by the publisher.*